doi: 10.4149/gpb_2024021

Protective role of S-adenosylmethionine on high fat/high cholesterol diet-induced hepatic and aortic lesions and oxidative stress in guinea pigs

İlknur Bingül[1], Canan Küçükgergin[1], Abdurrahman Fatih Aydın[1], Aydın Çevik[2], Merva Soluk-Tekkeşin[3], Vakur Olgaç[3], Semra Doğru-Abbasoğlu[1] and Müjdat Uysal[4]

[1] *Department of Medical Biochemistry, Istanbul Faculty of Medicine, Istanbul University, Istanbul, Turkey*
[2] *Aziz Sancar Experimental and Medical Research Institute, Istanbul University, İstanbul, Turkey*
[3] *Department of Pathology, Institute of Oncology, Istanbul University, Istanbul, Turkey*
[4] *Department of Medical Biochemistry, Istanbul Faculty of Medicine, Istanbul University, Istanbul, Turkey*

Abstract. S-adenosylmethionine (SAM) is the main methyl group donor and has antioxidant potential. In this study, preventive and regressive potential of SAM were investigated in high fat/high cholesterol (HFHC) diet-induced non-alcoholic fatty liver disease (NAFLD) in guinea pigs. They were injected with SAM (50 mg/kg, i.p.) for 6 weeks along with HFHC diet or 4 weeks after HFHC diet. Serum transaminase activities, total cholesterol (TC), triglyceride (TG), cytochrome p450-2E1 (CYP2E1) and hydroxyproline (Hyp) levels, prooxidative and antioxidative parameters, protein expressions of α-smooth muscle actin (α-SMA) and transforming growth factor-β1 (TGF-β1) together with histopathological changes were examined in the liver. SAM treatment diminished HFHC diet-induced increases in serum transaminase activities and hepatic TC, TG, CYP2E1, Hyp, α-SMA and TGF-β_1 expressions and ameliorated prooxidant-antioxidant balance. Histopathological scores for hepatic steatosis, inflammation, and fibrosis were decreased by SAM treatment. Increases in TC, diene conjugate levels, and lipid vacuoles within the tunica media of the aorta were reduced in HFHC-fed animals treated with SAM. These protective effects were also detected in the regression period of HFHC-guinea pigs due to SAM. In conclusion, SAM treatment was found to be effective in prevention and regression of HFHC-induced hepatic and aortic lesions together with decreases in oxidative stress in guinea pigs with NAFLD.

Key words: S-adenosylmethionine — Non-alcoholic steatohepatitis (NASH) — High fat/high cholesterol diet — Oxidative stress — Guinea pigs

Abbreviations: α-SMA, α-smooth muscle actin; ALT, alanine aminotransferase; AST, aspartate aminotransferase; CYP2E1, cytochrome p450-2E1; DC, diene conjugate; FRAP, ferric reducing antioxidant power; GSH, glutathione; HFHC, high fat/high cholesterol; Hyp, hydroxyproline; NAFLD, nonalcoholic fatty liver disease; NASH, non-alcoholic steatohepatitis; PC, protein carbonyl; REG, regression; ROS, reactive oxygen species; SAM, S-adenosylmethionine; TBARS, thiobarbituric acid reactive substances; TC, total cholesterol; TG, triglyceride; TGF-β1, transforming growth factor-β1; TNF-α, tumor necrosis factor α.

Correspondence to: İlknur Bingül, Department of Medical Biochemistry, Istanbul Faculty of Medicine, Istanbul University, Istanbul, Turkey
E-mail: ilknur.bingul@istanbul.edu.tr

© The Authors 2024. This is an **open access** article under the terms of the Creative Commons Attribution-NonCommercial 4.0 International License (https://creativecommons.org/licenses/by-nc/4.0/), which permits non-commercial use, distribution, and reproduction in any medium, provided the original work is properly cited.

Introduction

Non-alcoholic steatohepatitis (NASH) is a more severe form of non-alcoholic fatty liver disease (NAFLD) and is characterized by steatosis, inflammation and progressive fibrosis. A two-hit hypothesis for the pathogenesis of NASH has been proposed. Steatosis is the first hit and it enhances the hepatic susceptibility to subsequent secondary stresses such as oxidative stress, inflammation and cytokines and contributes to the development of NASH and other advanced pathologies in the liver (Noureddin et al. 2015).

S-adenosylmethionine (SAM) is a metabolic intermediate which is synthesized from dietary L-methionine and ATP by the enzyme methionine adenosyltransferase (MAT). It serves as the main methyl group donor and is used in transmethylation reactions in the organism. Its methyl group is transferred to various substrates such as DNA, RNA, proteins, lipids by methyl transferases, and after the transfer it turns into S-adenosylhomocysteine (Li et al. 2020). SAM has also direct and indirect antioxidant potential. It acts as direct antioxidant through mainly iron chelation and inhibition of Fe^{2+} autooxidation (Caro and Cederbaum 2004). SAM is a precursor of glutathione (GSH), a major cellular antioxidant, thus improving cellular ability to scavenge free radicals and inhibits cytochrome P450-2E1 (CYP2E1) enzyme activity (Cederbaum 2010). It also inhibits the production of proinflammatory molecules such as tumor necrosis factor α (TNF-α) and prevents mitochondrial dysfunction (Cederbaum 2010; Li et al. 2020). Therefore, SAM is accepted as a protective compound against hepatotoxic agents (Cederbaum 2010; Brown et al. 2014; Vincenzi et al. 2018). Moreover, SAM treatment protects against ischemia-reperfusion- (Valdes et al. 2023), cholestasis- (Brzački et al. 2019) and alcohol- (Gong et al. 2008) induced liver injuries and reduces fibrosis through inhibition of hepatic stellate cell activation in an ethanol-lipopolysaccharide-induced fibrotic model (Karaa et al. 2008).

SAM has a special importance in lipid metabolism *via* methylation of phosphatidylethanolamine to phosphatidylcholine (Noureddin et al. 2015). The decrease in hepatic SAM levels impairs the very low density lipoproteins (VLDL) export from the liver by decreasing phosphatidylcholine/phosphatidylethanolamine ratio and causes triglyceride (TG) accumulation in the liver. Low phosphatidylcholine/phosphatidyletanolamine ratio also increases membrane permeability and sensitizes the liver to endotoxin-induced proinflammatory cytokines (Noureddin et al. 2015; Mato et al. 2019). Low SAM levels were suggested to play a role in NASH development by serving as a second hit (Wortham et al. 2008; Noureddin et al. 2015; Mora et al. 2018). Indeed, although some investigators have found to be useful in the treatment of liver damage in experimental models of NAFLD and NASH (Oz et al. 2006; Bekyarova et al. 2017; Guo et al. 2021), both experimental and clinical studies are limited in this area (Anstee and Day 2012; Noureddin et al. 2015; Mora et al. 2018).

On the other hand, NAFLD/NASH is accepted as an effective factor that increases the risk of atherosclerotic cardiovascular diseases (Gaudio et al. 2012). The mechanisms leading to the formation and progression of atherosclerotic lesions are very similar to the mechanisms seen in NAFLD/NASH and oxidative stress plays an important role in the pathogenesis of both NAFLD and atherosclerosis (Gaudio et al. 2012; Polimeni et al. 2015). Some investigators have also suggested that SAM treatment may be useful in the prevention of endothelial dysfunction associated with atherosclerosis (Lim et al. 2011; Kim et al. 2013; Vergani et al. 2020).

Therefore, in this study, we investigated the effect of SAM treatment on high fat/high cholesterol (HFHC) diet-induced hepatic and aortic lesions in guinea pigs. The main purpose was to determine for the first time whether SAM has a preventive and/or regressive potential on hepatic and aortic injuries and oxidative stress in HFHC-treated guinea pigs.

Materials and Methods

Chemicals

The chemical, S-adenosyl-L methionine disulfate tosylate was donated by Pure Encapsulations, Inc. (Sudbury, MA, USA). Cholesterol was purchased from Alfa Easer (Kandel, Germany), and other chemicals were obtained from Sigma-Aldrich (Darmstadt, Germany).

Animals and experimental design

Dankin-Hartley guinea pigs, weighing 600–650 g, were obtained from Aziz Sancar Experimental and Medical Research Institute of Istanbul University. All animals were housed in a stainless steel cage (two or three *per* cage) with temperature and light control, 12 h dark and 12 h light. The experimental procedures used in this study were approved by the Animal Care and Use Committee of Istanbul University (Approval No: 02.03.2108-2018/18).

To investigate preventive and regressive effects of SAM treatment on hepatic and aortic lesions and oxidative stress in HFHC-treated guinea pigs, animals were divided into five groups: a) Control group: guinea pigs were fed a commercial guinea pig chow and injected for 0.9% NaCl as vehicle for 6 weeks. b) HFHC group: guinea pigs were fed on HFHC diet containing 81% standard guinea pig chow diet, 1% cholesterol, 8% yolk powder and 10% beef tallow for 6 weeks. c) SAM+HFHC group: animals were fed on

HFHC diet together with SAM injection (50 mg/kg; freshly dissolved in 0.9% NaCl solution; 5 days *per* week; i.p.) for 6 weeks. d) Regression groups: guinea pigs fed on HFHC diet for 6 weeks were divided into 2 regression groups and fed control diet for an additional 4-week period. First regression group was injected with 0.9% NaCl as vehicle of SAM (REG group). However, the second regression group was injected with SAM (50 mg/kg; freshly dissolved in 0.9% NaCl solution; 5 days *per* week) intraperitoneally for 4 weeks (SAM+REG group).

Diets were prepared by the Barbaros Denizeri Company (Gebze) and kept at 4°C. The animals were allowed free access to food and water. To avoid differences in the amount of consumed food and drinking water between groups, intake of food and water was periodically monitored.

Samples

At the end of the experimental period guinea pigs were fasted overnight and anesthetized with ketamine (40 mg/kg, i.p., Pfizer, USA) and xylazine HCl (5 mg/kg, i.p., Bioveta, Czech Republic) anesthesia. Blood samples were taken into dry tubes by cardiac puncture and then, they were centrifuged at 1500×*g* for 10 min to separate the sera. Liver tissues were rapidly removed, washed in 0.9% NaCl and homogenized in ice-cold phosphate-buffered saline (PBS; 0.01 M, pH 7.4). Tissue homogenates were centrifuged at 600×*g* for 10 min at 4°C and post-nuclear supernatants (PNS) were used for biochemical analyses of the liver. The aorta, from the aortic valve to the renal artery, was quickly removed, rinsed and cut into small segments. Serum and tissues were stored at –80°C until analyzed.

Determinations in serum

Total cholesterol (TC) and triglyceride (TG) levels and alanine aminotransferase (ALT) and aspartate aminotransferase (AST) activities were measured by using a Cobas Integra 800 autoanalyzer (Roche Diagnostics, Mannheim, Germany). TNF-α level was measured using ELISA kits (Abbkine, Wuhan, China).

Determinations in liver

Hepatic SAM (Sunred Bio, Shanghai, China), hydroxyproline (Hyp) (Bioassay Technology Laboratory, Shanghai, China) and CYP2E1 (Abbkine, Wuhan, China) levels were measured in PNS samples obtained from liver homogenates by using ELISA kits according to manufacturers' instructions. Hepatic TC and TG levels were measured using commercial colorimetric kits (Biolabo Biochemistry and Coagulation, Maizy, France) in lipid extracts obtained from the tissues.

Reactive oxygen species (ROS) levels generation was determined using a fluorometric assay (Wang and Joseph 1999). For this reason, PNS samples of liver homogenates were incubated with 100 μM 2′,7′-dichlorodihydrofluorescein diacetate to form 2′,7′-dichlorofluorescein by cellular esterases. The fluorescence of 2′,7′-dichlorofluorescein was determined using a microplate fluorimeter and luminometer (Fluoroskan Ascent FL, Thermo Scientific Inc., USA) with an excitation of 485 nm and emission of 538 nm. Hepatic lipid peroxidation was evaluated by the determination of thiobarbituric acid reactive substances (TBARS) and diene conjugate (DC) levels. For TBARS determination, especially malondialdehyde levels were measured using the method of Buege and Aust (1978). The absorbance of the samples was recorded at 532 nm and the results were calculated using the extinction coefficient (1.56×10^{-5} $M^{-1}cm^{-1}$). DC levels were determined spectrophotometrically at 233 nm in lipid extracts. They were dissolved in cyclohexane, and the amounts of DC levels were calculated using a molar extinction coefficient of 2.52×10^{4} $M^{-1}cm^{-1}$ (Buege and Aust 1978). Oxidative protein damage was quantified by measuring carbonyl groups based on spectrophotometric detection of the protein hydrazones formed by the reaction between 2,4-dinitrophenylhydrazine and protein carbonyl (PC) groups (Reznick and Packer 1994). Hepatic PC levels were calculated from the maximum absorbance (360 nm) using a molar extinction coefficient of 22.000 $M^{-1}cm^{-1}$. GSH levels were measured in the PNS samples of homogenates with 5,5-dithiobis-(2-nitrobenzoate) at 412 nm (Beutler et al. 1963). Ferric reducing antioxidant power (FRAP) assay was used for the determination of antioxidant power of liver homogenates. A ferric-tripyridyltriazine complex is reduced to its ferrous form by electron-donating antioxidants present in liver tissue. The reaction is monitored by measuring the change in absorption at 593 nm (Benzie and Strain 1996). Protein levels in liver homogenates were assayed by bicinchoninic acid using serum albumin as standard (Smith et al. 1985).

Determinations in aorta

TC and DC levels were determined in lipid extracts of the aorta using the same method as in liver tissue.

Histopathological analysis

Pieces of liver and aorta were fixed in 10% buffered formalin, embedded in paraffin, sectioned and stained with hematoxylin and eosin (H&E) for histologic examinations. Reticulin staining was also performed to show reticulin fibers of fibrotic areas in the liver. Steatosis, liver damage and fibrosis scores were made according to the protocol proposed by Goodman (2007) previously reported by us (Bingül et al. 2016).

Immunohistochemical analysis of α-SMA and TGF-β-1

Liver sections were incubated with the following primary antibodies: α-SMA (dilution 1:100, ABP52852, rabbit polyclonal, Abbkine, Wuhan, China) and TGF-β-1 (dilution 1:100, APB52598, rabbit polyclonal, Abbkine, Wuhan, China) for 1 hour at room temperature. Negative control sections treated with phosphate-buffered antibodies were confirmed to be unstained. The secondary antibody was reacted for 25 min. AEC (ScyTek Laboratories, Inc.205 South 600 West Logan, UT 84321, USA) chromogen was used to visualize the reaction. Finally, the sections were counterstained with Mayer's hematoxylin, coverslipped, and evaluated by a light microscope.

Statistical analysis

Statistical analysis was evaluated by using the Statistical Package for Social Sciences program (21.0; SPSS Inc., Chicago, IL, USA) program. All variables were given as mean ± standard deviation (SD). Data distributions and test of normality were investigated by Shapiro-Wilk test. One-way ANOVA test (*post-hoc* Tukey's test) was used to assess the parameters with normal distribution. Homogeneity of variances was evaluated with Levene test. Kruskal-Wallis test (*post-hoc* Mann Whitney-U test) was used to compare the parameters without normal distribution. In all cases, a difference was considered significant when $p < 0.05$.

Results

Changes in body and liver weights, liver index and serum parameters

There were no significant changes in body weight in HFHC and SAM+HFHC groups compared to controls. Significant increases in liver weight and liver index were detected in HFHC group as compared to control, but SAM treatment did not alter liver weight and liver index in HFHC-guinea pigs. Serum TC and TNF-α levels and ALT and AST activities increased significantly, but TG levels remained unchanged in HFHC group. SAM treatment diminished significantly TNF-α levels and ALT and AST activities, but TC and TG levels did not alter in HFHC-fed animals.

Guinea pigs in the HFHC group were fed with the HFHC diet for 6 weeks, followed by a regression period in which they were fed normal chow for 4 weeks. At the end of this period, there was no change in body and liver weights, liver index, serum TC, TG and TNF-α levels, and ALT and AST activities. When SAM was applied to HFHC guinea pigs during the regression period, liver weight and liver index, as well as serum TC levels, ALT and AST activities showed significant decreases (Table 1).

Changes in liver histology

Histopathological findings in the liver are shown in Figure 1. Normal hepatic architecture was seen in control group. Dif-

Table 1. The effect of S-adenosylmethionine (SAM) treatment on body weight, liver weight and liver index values and serum parameters in guinea pigs fed on HFHC diet

	Control ($n = 6$)	HFHC ($n = 6$)	SAM+HFHC ($n = 6$)	REG ($n = 6$)	SAM+REG ($n = 6$)
Body weight (g)	750.0 ± 41.5	719.0 ± 72.1	728.0 ± 60.0	743.2 ± 62.9	696.3 ± 74.9
Liver weight (g)	35.1 ± 3.44	55.1 ± 8.28[a]	50.3 ± 5.99[a]	48.5 ± 6.62[a]	42.5 ± 4.55[b]
Liver index (%)	4.68 ± 0.53	7.71 ± 1.36[a]	6.91 ± 0.39[a]	6.52 ± 0.61[a]	6.12 ± 0.55[a,b]
TC (mmol/l)	1.51 ± 0.46	5.71 ± 1.03[a]	4.61 ± 1.28[a]	5.83 ± 1.30[a]	3.46 ± 0.65[a,b]
TG (mmol/l)	0.82 ± 0.10	0.96 ± 0.19	0.90 ± 0.16	0.89 ± 0.15	0.94 ± 0.22
TNF-α (ng/l)	18.6 ± 2.52	22.2 ± 1.91[a]	16.1 ± 1.39[b]	21.7 ± 1.81	20.4 ± 2.18
ALT (U/l)	51.0 ± 5.32	120.7 ± 47.9[a]	62.2 ± 6.36[a,b]	84.0 ± 18.5[a]	68.5 ± 10.6[a,b]
AST (U/l)	96.3 ± 14.0	597.0 ± 98.7[a]	401.8 ± 31.5[a,b]	370.0 ± 132.1[a]	303.0 ± 63.0[a,b]

Data are mean ± SD. REG, regression period following HFHC feeding. [a] $p < 0.05$ *vs.* control group; [b] $p < 0.05$ *vs.* HFHC group.

Table 2. The effect of S-adenosylmethionine (SAM) treatment on steatosis, inflammation and fibrosis scores in the liver of guinea pigs fed on HFHC diet

	Control ($n = 6$)	HFHC ($n = 6$)	SAM+HFHC ($n = 6$)	REG ($n = 6$)	SAM+REG ($n = 6$)
Steatosis	0.00 ± 0.00	2.83 ± 0.41[a]	2.17 ± 0.40[a,b]	2.33 ± 0.82[a]	1.50 ± 0.55[a,b]
Inflammation	0.00 ± 0.00	1.33 ± 0.81[a]	0.50 ± 0.54	0.83 ± 0.75[a]	0.50 ± 0.84
Fibrosis	0.00 ± 0.00	3.33 ± 0.52[a]	2.50 ± 0.54[a,b]	2.83 ± 0.41[a]	2.00 ± 0.00[a,b]

Data are mean ± SD. REG, regression period following HFHC feeding. [a] $p < 0.05$ *vs.* control group; [b] $p < 0.05$ *vs.* HFHC group.

fuse macrovesicular steatosis, mild lympocytic infiltration, arrowing in sinusoids and fibrosis in the form of fine bridging were detected between the central-portal regions. These fibrous bridging areas were highlighted and reticulin fibers running parallel were observed by reticulin stain in HFHC group. However, in SAM+HFHC group, steatosis findings were regressed. Hepatocytes appeared close to native histology around the central and portal veins. In addition, fibrous bands decreased and fibrous bridges between portal-central regions lost their continuity in this group. Although the histological changes seen in the HFHC group still continued in REG group, in SAM-treated regression period, natural histology was detected in more area in liver tissue and fibrous bands appear to be thinner and shorter than HFHC group.

Hepatic steatosis, inflammation and fibrosis scores are evaluated in Table 2. SAM treatment diminished significantly the increases in steatosis, inflammation and fibrosis scores in HFHC group, but decrease in inflammation score was not significant. Although these scores did not alter in regression group, steatosis and fibrosis scores decreased

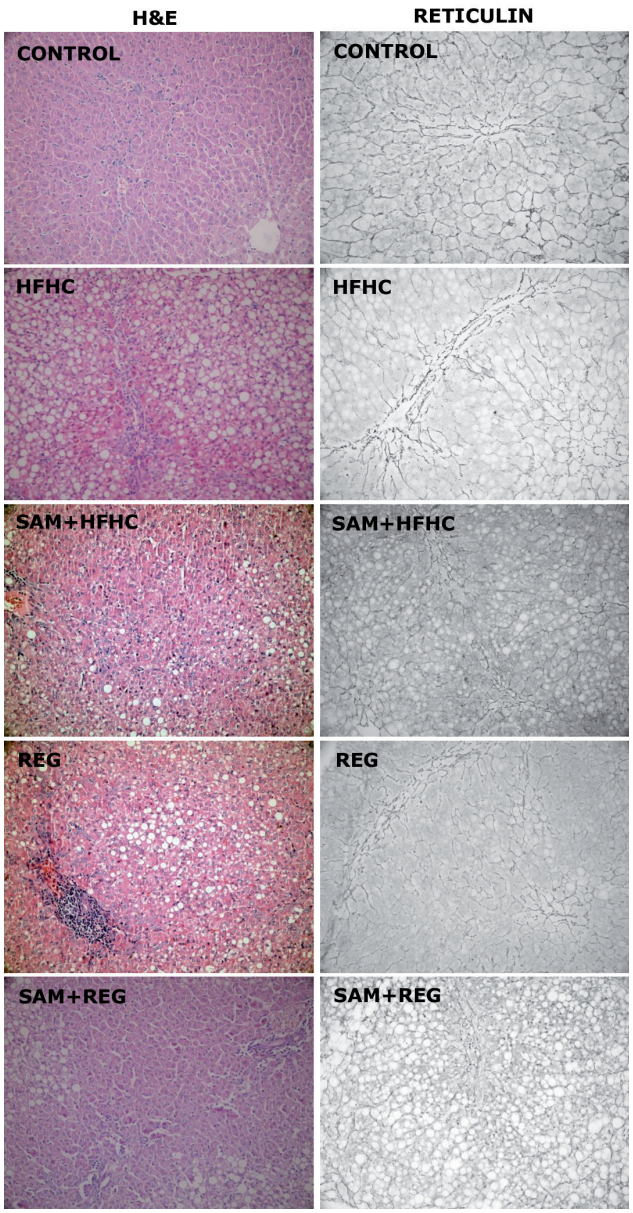

Figure 1. The effect of S-adenosylmethionine (SAM) treatment on hepatic histopathology of guinea pigs fed on HFHC diet (H&E ×200, Reticulin ×200).

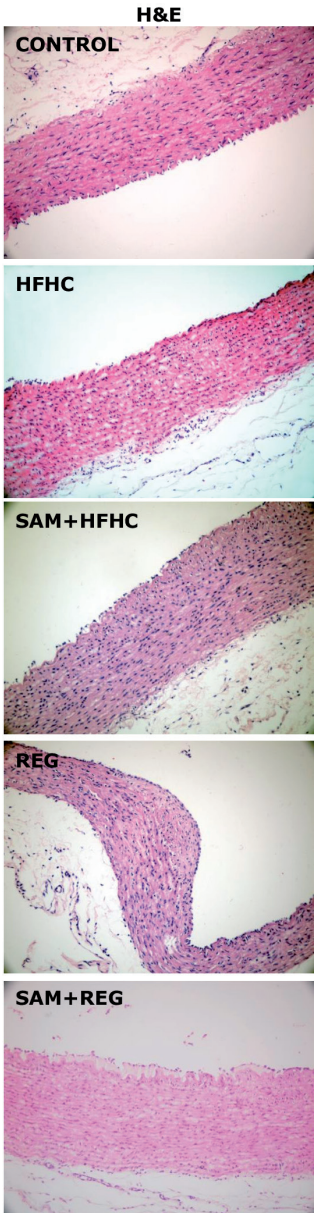

Figure 2. The effect of S-adenosylmethionine (SAM) treatment on aortic histopathology of guinea pigs fed on HFHC diet (H&E ×200).

significantly in SAM-treated regression group as compared to HFHC group.

Changes in aortic histology

Histopathological findings obtained from H&E staining aorta sections are shown in Figure 2. Normal aorta histology was observed in control group. Spaces of fat droplets within tunica media were observed in the aorta of HFHC group. The aorta of SAM+HFHC group showed less spaces of fat droplets as compared to HFHC group. The same histology seen in HFHC group was also detected following regression. However, in SAM+REG group, slight decreases in lipid vacuoles were observed in the media.

Changes in hepatic TC, TG, SAM, Hyp and CYP2E1 levels

Significant elevations in TC, TG, Hyp and CYP2E1 levels and reduction in SAM levels were detected in HFHC group. Although there were no changes in TC levels, TG, Hyp and CYP2E1 levels decreased, but SAM levels increased in the liver of SAM-treated HFHC group. Decreases in TC, TG, Hyp and CYP2E1 levels and increases in SAM levels were also obtained in SAM+REG group, but not REG group as compared to HFHC group (Fig. 3).

Changes in hepatic prooxidant and antioxidant parameters

Significant increases in hepatic ROS, TBARS, DC and PC levels and decreases in GSH and FRAP levels were found in HFHC group. SAM treatment decreased significantly ROS, TBARS, DC and PC levels and increased GSH and FRAP levels in guinea pigs fed on HFHC diet. There were also significant decreases in ROS, TBARS, DC and PC levels and increases in GSH levels in SAM+REG group, but not REG group as compared to HFHC group (Fig. 4 and Table 3).

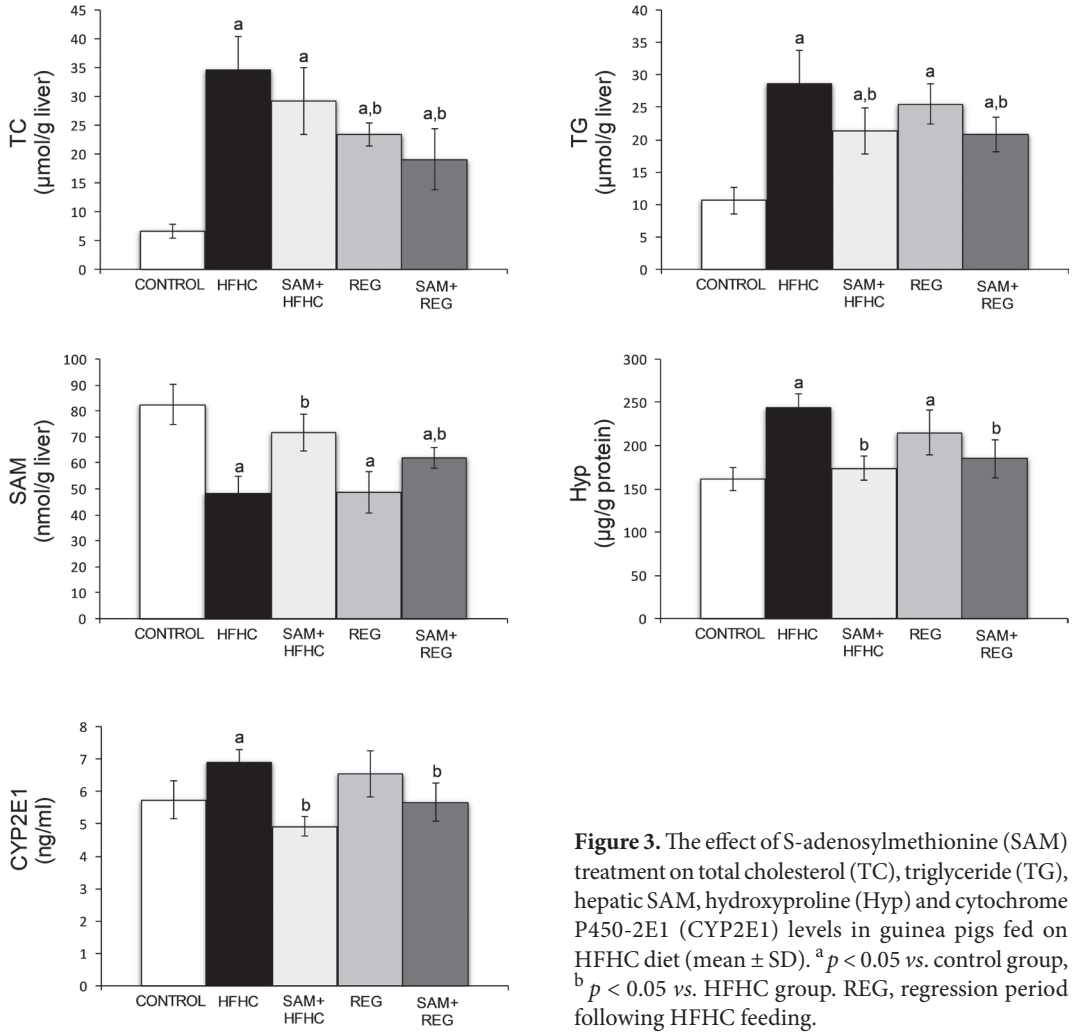

Figure 3. The effect of S-adenosylmethionine (SAM) treatment on total cholesterol (TC), triglyceride (TG), hepatic SAM, hydroxyproline (Hyp) and cytochrome P450-2E1 (CYP2E1) levels in guinea pigs fed on HFHC diet (mean ± SD). [a] $p < 0.05$ *vs.* control group, [b] $p < 0.05$ *vs.* HFHC group. REG, regression period following HFHC feeding.

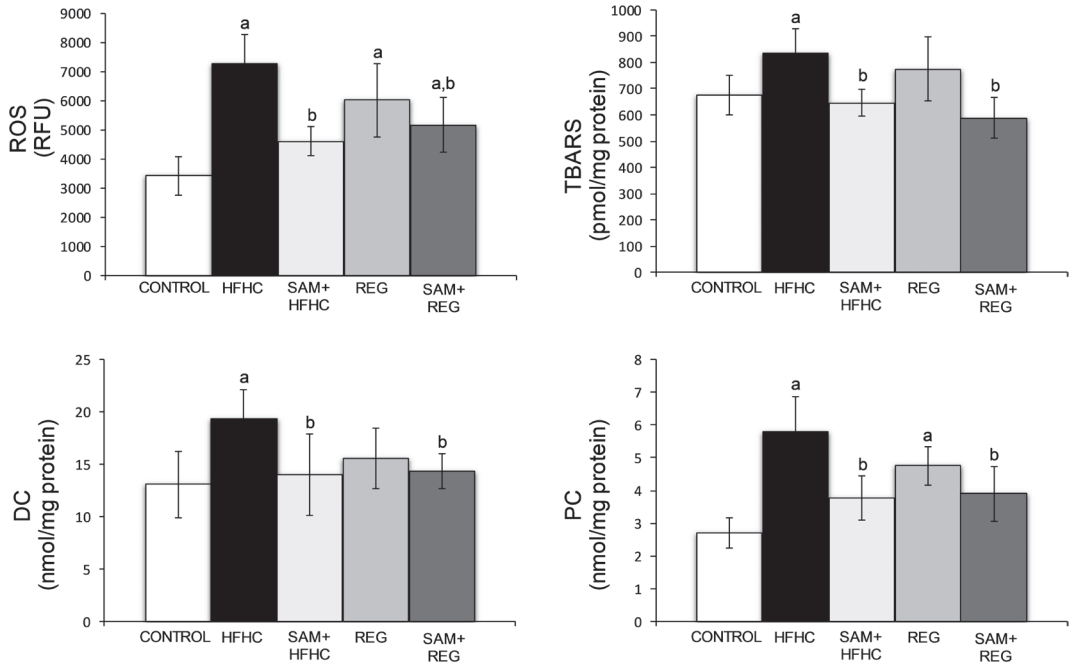

Figure 4. Hepatic reactive oxygen species (ROS), thiobarbituric acid reactive substances (TBARS), diene conjugate (DC) and protein carbonyl (PC) levels in guinea pigs fed on HFHC diet (mean ± SD). [a] $p < 0.05$ *vs.* control group, [b] $p < 0.05$ *vs.* HFHC group. REG, regression period following HFHC feeding.

Changes in hepatic α-SMA and TGF-β1 protein expressions

Significant increases in α-SMA and TGF-β1 protein expressions were detected in guinea pigs fed on HFHC diet. These expressions decreased in SAM-treated HFHC group. Similarly, α-SMA and TGF-β1 protein expressions were also observed to decrease markedly in SAM+REG group as compared to HFHC group. However, there were no changes in expressions of these parameters in REG group (Fig. 5).

Changes in TC and DC levels in the aorta

Aorta TC and DC levels augmented significantly in HFHC group. SAM treatment decreased aorta TC and DC levels in guinea pigs fed on HFHC diet. In SAM+REG group, aorta TC and DC levels were also decreased significantly in SAM+REG ($p < 0.01$) and REG ($p < 0.05$) groups as compared to HFHC group (Table 3).

Discussion

Some dietary experimental models such as methionine choline deficient (MCD), high fat (HF), high fructose (HFr) and high cholesterol (HC) diets and their combinations have been used to understand the pathogenesis of NAFLD/NASH (Takahashi et al. 2012). It has been suggested that HF-diet together with HC-diet interact synergistically to induce NASH (Savard et al. 2013). HC containing diets are also a risk factor for atherosclerosis as in NASH. Therefore, HFHC diet

Table 3. The effect of S-adenosylmethionine (SAM) treatment on hepatic glutathione (GSH) and ferric reducing antioxidant power (FRAP) levels in the liver as well as aortic total cholesterol (TC) and diene conjugate (DC) levels in the aorta of guinea pigs fed on HFHC diet

	Control ($n = 6$)	HFHC ($n = 6$)	SAM+HFHC ($n = 6$)	REG ($n = 6$)	SAM+REG ($n = 6$)
GSH (nmol/mg protein)	50.3 ± 4.41	37.7 ± 3.64[a]	59.9 ± 7.38[b]	45.6 ± 7.46	54.8 ± 8.94[b]
FRAP (nmol/mg protein)	98.1 ± 14.9	53.2 ± 15.5[a]	78.1 ± 11.9[b]	63.1 ± 11.5[a]	69.5 ± 10.5[a]
TC (μmol/g aorta)	3.25 ± 0.75	6.67 ± 0.62[a]	5.10 ± 0.53[a,b]	5.07 ± 0.96[a,b]	4.75 ± 1.01[a,b]
DC (μmol/g aorta)	2.64 ± 0.21	3.55 ± 0.58[a]	2.97 ± 0.26[a,b]	3.00 ± 0.20[a,b]	2.89 ± 0.26[b]

Data are mean ± SD. REG, regression period following HFHC feeding. [a] $p < 0.05$ *vs.* control group; [b] $p < 0.05$ *vs.* HFHC group.

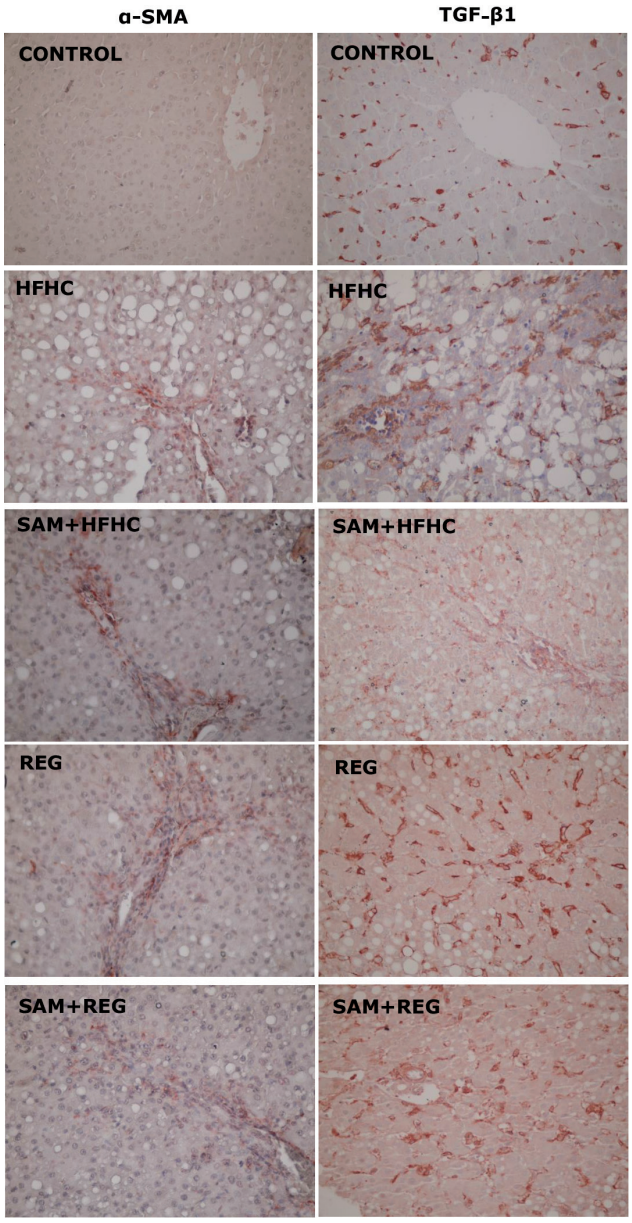

Figure 5. The effect of S-adenosylmethionine (SAM) treatment on hepatic α-smooth muscle actin (α-SMA) and transforming growth factor- β1 (TGF-β1) protein expression of guinea pigs fed on HFHC diet (×400). REG, regression period following HFHC feeding.

is accepted as an appropriate dietary experimental model for NASH and atherosclerosis. Guinea pigs are very susceptible to the development of HFHC induced NASH and atherosclerosis (Ye et al. 2013). Therefore, in this study, guinea pigs were used as experimental animals.

In this study, HFHC diet was observed to increase serum ALT and AST activities and TNF-α levels, hepatic TC and TG levels together with increases in steatosis, inflammation and fibrosis scores in the liver histopathology in guinea pigs. Increases in hepatic Hyp levels and profibrotic α-SMA and TGF-β1 protein expressions are indicators of fibrosis formation. As it is known, activated hepatic stellate cells (HSC) is known to be the main fibrogenic cell and HSC activation is crucial in liver fibrogenesis. TGF-β1 is a key cytokine in the pathogenesis of liver fibrosis and α-SMA is a marker of activated HSCs (Karaa et al. 2008; Bingül et al. 2016).

CYP2E1-generated ROS plays an important role in the induction of oxidative stress in NAFLD (Cederbaum 2010; Harjumaki et al. 2021). TBARS and DC levels are indicators of lipid peroxidation, however, PC levels are indicators of protein oxidation. In this study, hepatic ROS, TBARS, DC and PC levels elevated in HFHC guinea pigs. In these conditions, decreases in hepatic GSH may be related to its increased consumption as a potent intracellular antioxidant molecule. Additionally, the FRAP assay is a global marker for antioxidant power (Benzie and Strain 1996). Decreases in FRAP levels in the liver of guinea pigs with NASH also reflects an insufficiency in antioxidant power. These findings show that a prooxidant state developed in the liver of guinea pigs fed on HFHC. Our results obtained from HFHC guinea pigs are in accordance with previous results in the liver of guinea pigs (Çoban et al. 2013; Zhang et al. 2013; Ipsen et al. 2016; Bekyarova et al. 2017; Küskü-Kiraz et al. 2018).

Decreased SAM levels in chronic liver disease may be related to enhanced consumption of this substance as an antioxidant and/or its reduced synthesis *via* inhibition of MAT1A, an oxidation sensitive enzyme (Anstee and Day 2012; Ramani and Lu 2017). MAT1A-deficient mice were detected to show spontaneous steatosis and its progression to NASH, and SAM treatment reduced hepatic damage, ALT and AST activities, and TG levels in these mice (Mato et al. 2019). Therefore, it has been suggested that SAM homeostasis may have an active role in the pathogenesis of NAFLD and that SAM supplementation can be used as a treatment tool in NAFLD (Wortham et al. 2008; Noureddin et al. 2015). However, experimental (Oz et al. 2006; Lieber et al. 2007; Bekyarova et al. 2017) studies on this subject are limited. In addition, the mechanisms by which SAM is effective in NAFLD are not well known. In mice with NASH induced by MCD diet, SAM administration ameliorated liver damage by increasing hepatic SAM and GSH levels and downregulating gene expressions of inflammatory and fibrogenic cytokines (Oz et al. 2006). Similarly, the administration of SAM decreased microvesicular steatosis, malondialdehyde levels and apoptosis in the liver of rats fed a HFr-diet (Bekyarova et al. 2017). However, Lieber et al. (2007) have reported that although SAM or dilinoleylphosphatidylcholine (DLPC) alone was not effective, combination of SAM with DLPC prevented CYP2E1 activation, TG accumulation, oxidative stress and fibrotic changes in the liver of rats fed on HF diet. However, in a recent study, it was found that SAM reduced steatosis in rats fed on HF diet by upregulating an-

giotensin II receptor 1(AT1R)-associated protein (ATRAP), which is the primary receptor of angiotensin II (Ang II) in the renin-angiotensin system (RAS) (Guo et al. 2021). Since the activation of RAS system was reported to be effective as a second hit in NAFLD progression (Wu et al. 2016), this activity along with other activities of SAM may indicate its useful as a therapeutic agent in NAFLD.

In this study, SAM was injected to animals at the same time period with HFHC diet to evaluate its preventive potential against liver lesions. The SAM dose and duration used in our study are based on some previous studies (Gong et al. 2008; Kim et al. 2013; Bekyarova et al. 2017). SAM treatment decreased serum ALT and AST activities, TNF-α levels and liver TG levels and steatosis score without any change in liver TC levels in guinea pigs fed on HFHC. Decreases in profibrotic α-SMA and TGF-β1 protein expressions, Hyp levels and fibrosis score were also detected. Therefore, inhibition of HSC activation may play a role in antifibrogenic efficiency of SAM in HFHC-fed guinea pigs as previously reported (Karaa et al. 2008). This treatment was also found to decrease hepatic CYP2E1, ROS, lipid and protein oxidation products and increase hepatic GSH and FRAP levels. These results indicated that SAM diminished prooxidant state in the liver of HFHC-fed guinea pigs.

On the other hand, there is an association between NAFLD and endothelial dysfunction (Gaudio et al. 2012). Endothelial dysfunction has been recognized as the early symbol of atherosclerosis and plays a role in its development and progression. SAM supplementation ameliorated endothelial dysfunction in HFD rats (Kim et al. 2013) and prevented neointimal formation after balloon injury in obese diabetic rats (Lim et al. 2011). In addition, in *in vitro* conditions, SAM was detected to decrease fatty acid-induced lipid accumulation and attenuate oxidative stress in endothelial cells (Vergani et al. 2020). However, there is no adequate knowledge related to the effect of SAM supplementation on aortic lesions in experimental NAFLD models. In this study, HFHC diet caused increases in aortic TC and DC levels and accumulation of lipid vacuoles in the aortas. Our findings indicate that HFHC-induced atherosclerotic changes were produced as previously reported (Amran et al. 2009; Çoban et al. 2013; Ye et al. 2013) and SAM treatment decreased aortic TC and DC levels and improved aortic histology in guinea pigs with NASH.

In our study, SAM was also applied to guinea pigs fed on normal diet in 4-week regression period following HFHC diet to assess its regressive potential of SAM. Obtained results indicate that SAM treatment was also effective in the regression of HFHC-induced hepatic lesions such as steatosis, inflammation and fibrosis together with decreases in oxidative stress parameters. Decreases in TC and DC levels and an improvement of aortic histopathological findings were observed in aortas of SAM+REG group.

In conclusion, this study indicates that SAM treatment has preventive and regressive efficiency in HFHC-induced hepatic injury and oxidative stress. Moreover, an improvement in aortic findings was also observed. These beneficial effects of SAM in guinea pigs fed on HFHC diet may be related to its multifunctional properties such as antioxidant, antiinflammatory, antisteatotic and antifibrotic activities.

Acknowledgement. We gratefully thank Mr. E. Paul Larkin from Atrium Innovation Inc. for supporting us in providing S-adenosylmethionine material.

Conflict of interest. The authors declare no conflict of interest.

Funding. The present work was supported by Research Fund of Istanbul University (Project No: 30446).

References

Amran AA, Zaiton Z, Faizah O, Morat P (2009): Effects of Garcinia atroviridis on serum profiles and atherosclerotic lesions in the aorta of guinea pigs fed a high cholesterol diet. Singapore Med. J. **50,** 295-299

Anstee QM, Day CP (2012): S-adenosylmethionine (SAMe) therapy in liver disease: A review of current evidence and clinical utility. J. Hepatol. **57,** 1097-1109 https://doi.org/10.1016/j.jhep.2012.04.041

Bekyarova G, Tzaneva M, Bratoeva K, Kotzev I, Radanova M (2017): Heme-oxygenase-1 upregulated by S-adenosylmethionine. Potential protection against non-alcoholic fatty liver induced by high fructose diet. Farmacia **65,** 262-267

Benzie IFF, Strain JJ (1996): The ferric reducing ability of plasma (FRAP) as a measure of ‚antioxidant power“: the FRAP assay. Anal. Biochem. **239,** 70-76 https://doi.org/10.1006/abio.1996.0292

Beutler E, Duron O, Kelly BM (1963): Improved method for the determination of blood glutathione. J. Lab. Clin. Med. **61,** 882-888

Bingül İ, Aydın AF, Başaran-Küçükgergin C, Doğan-Ekici I, Çoban J, Doğru-Abbasoğlu S, Uysal M (2016): High-fat diet plus carbon tetrachloride-induced liver fibrosis is alleviated by betaine treatment in rats. Int. Immunopharmacol. **39,** 199-207 https://doi.org/10.1016/j.intimp.2016.07.028

Brown JM, Kuhlman C, Terneus MV, Labenski MT, Lamyaithong AB, Ball JG, Lau SS, Valentovic MA (2014): S-adenosyl-L-methionine protection of acetaminophen mediated oxidative stress and identification of hepatic 4-hydroxynonenal protein adducts by mass spectrometry. Toxicol. Appl. Pharmacol. **281,** 174-184 https://doi.org/10.1016/j.taap.2014.08.027

Brzački V, Mladenović B, Dimić D, Jeremić L, Živanović D, Djukić D, Stojanović NM, Sokolović DT (2019): Comparison between the effects of selenomethionine and S-adenosylmethionine in preventing cholestasis-induced rat liver damage. Amino Acids **51,** 795-803 https://doi.org/10.1007/s00726-019-02716-3

Buege JA, Aust SD (1978): Microsomal lipid peroxidation. Methods Enzymol. **52,** 302-310
https://doi.org/10.1016/S0076-6879(78)52032-6

Caro AA, Cederbaum AI (2004): Antioxidant properties S-adenosyl-L-methionine in Fe2+-initiated oxidations. Free Radic. Biol. Med. **36,** 1303-1316
https://doi.org/10.1016/j.freeradbiomed.2004.02.015

Cederbaum AI (2010): Hepatoprotective effects of S-adenosyl-L-methionine against alcohol- and cytochrome P450 2E1-induced liver injury. World J. Gastroenterol. **16,** 1366-1376
https://doi.org/10.3748/wjg.v16.i11.1366

Çoban J, Evran B, Özkan F, Çevık A, Doğru-Abbasoğlu S, Uysal M (2013): Effect of blueberry feeding on lipids and oxidative stress in the serum, liver and aorta of guinea pigs fed on a high-cholesterol diet. Biosci. Biotechnol. Biochem. **277,** 389-391
https://doi.org/10.1271/bbb.120722

Gaudio E, Nobili V, Franchitto A, Onori P, Carpino G (2012): Nonalcoholic fatty liver disease and atherosclerosis. Intern. Emerg. Med. **3,** S297-305
https://doi.org/10.1007/s11739-012-0826-5

Gong Z, Yan S, Zhang P, Huang Y, Wang L (2008): Effects of S-adenosylmethionine on liver methionine metabolism and steatosis with ethanol-induced liver injury in rats. Hepatol. Int. **2,** 346-352
https://doi.org/10.1007/s12072-008-9082-1

Goodman ZD (2007): Grading and staging systems for inflammation and fibrosis in chronic liver diseases. J. Hepatol. **47,** 598-607
https://doi.org/10.1016/j.jhep.2007.07.006

Guo T, Dai Z, You K, Battaglia-Hsu SF, Feng J, Wang F, Li B, Yang J, Li Z (2021): S-adenosylmethionine upregulates the angiotensin receptor-binding protein ATRAP via the methylation of HuR in NAFLD. Cell. Death Dis. **12,** 306
https://doi.org/10.1038/s41419-021-03591-1

Harjumaki R, Pridgeon CS, Ingelman-Sundberg M (2021): CYP2E1 in alcoholic and non-alcoholic liver injury. Roles of ROS, reactive intermediates and lipd overload. Int. J. Mol. Sci. **22,** 8221
https://doi.org/10.3390/ijms22158221

Ipsen DH, Tveden-Nyborg P, Rolin B, Rakipovski G, Beck M, Mortensen LW, Faerk L, Heegaard PMH, Moller P, Lykkesfeldt J (2016): High-fat but not sucrose intake is essential for induction of dyslipidemia and non-alcoholic steatohepatitis in guinea pigs. Nutr. Metab. (Lond). **13,** 51
https://doi.org/10.1186/s12986-016-0110-1

Karaa A, Thompson KJ, McKillop IH, Clemens MG, Schrum LW (2008): S-adenosyl-L-methionine attenuates oxidative stress and hepatic stellate cell activation in an ethanol-LPS-induced fibrotic rat model. Shock **30,** 197-205
https://doi.org/10.1097/SHK.0b013e318160f417

Kim SY, Hong SW, Kim MO, Kim HS, Jang JE, Leem J, Park IS, Lee KU, Koh EH (2013): S-adenosyl methionine prevents endothelial dysfunction by inducing heme oxygenase-1 in vascular endothelial cells. Mol. Cells **36,** 376-384
https://doi.org/10.1007/s10059-013-0210-y

Küskü-Kiraz Z, Genc S, Bekpınar S, Ünlücerci Y, Çevik A, Olgaç V, Gurdol F, Uysal M (2018): Effects of betaine supplementation on nitric oxide metabolism, atherosclerotic parameters, and fatty liver in guinea pigs fed a high cholesterol plus methionine diet. Nutrition **45,** 41-48
https://doi.org/10.1016/j.nut.2017.07.005

Li Z, Wang F, Liang B, Su Y, Sun S, Xia S, Shao J, Zhang Z, Hong M, Zhang F, Zheng S (2020): Methionine metabolism in chronic liver diseases: an update on molecular mechanism and therapeutic implication. Signal. Transduct. Target Ther. **5,** 280
https://doi.org/10.1038/s41392-020-00349-7

Lieber CS, Leo MA, Cao Q, Mak KM, Ren C, Ponomarenko A, Wang X, DeCarli LM (2007): The combination of S-adenosylmethionine and dilinoleoylphosphatidylcholine attenuates non-alcoholic steatohepatitis produced in rats by a high-fat diet. Nutr. Res. **27,** 565-573
https://doi.org/10.1016/j.nutres.2007.07.005

Lim S, Moon MK, Shin H, Kim TH, Cho BJ, Kim M, Park HS, Choi SH, Ko SH, Chung MH, et al. (2011): Effect of S-adenosylmethionine on neointimal formation after balloon injury in obese diabetic rats. Cardiovasc. Res. **90,** 383-393
https://doi.org/10.1093/cvr/cvr009

Mato JM, Alonso C, Noureddin M, Lu SC (2019): Biomarkers and subtypes of deranged lipid metabolism in nonalcoholic fatty liver disease. World J. Gastroenterol. **25,** 3009-3020
https://doi.org/10.3748/wjg.v25.i24.3009

Mora SI, Garcia-Roman J, Gomez-Nanez I, Garcia-Roman R (2018): Chronic liver diseases and the potential use of S-adenosyl-L-methionine as a hepatoprotector. Eur. J. Gastroenterol. Hepatol. **30,** 893-900
https://doi.org/10.1097/MEG.0000000000001141

Noureddin M, Mato JM, Lu SC (2015): Nonalcoholic fatty liver disease: update on pathogenesis, diagnosis, treatment and the role of S-adenosylmethionine. Exp. Biol. Med. **240,** 809-820
https://doi.org/10.1177/1535370215579161

Oz HS, Im HJ, Chen TS, de Villiers WJ, McClain CJ (2006): Glutathione-enhancing agents protect against steatohepatitis in a dietary model. J. Biochem. Mol. Toxicol. **20,** 39-47
https://doi.org/10.1002/jbt.20109

Polimeni L, Del Ben M, Baratta F, Perri L, Albanese F, Pastori D, Violi F, Angelico F (2015): Oxidative stress: New insights on the association of non-alcoholic fatty liver disease and atherosclerosis. World J. Hepatol. **7,** 1325-1336
https://doi.org/10.4254/wjh.v7.i10.1325

Ramani K, Lu SC (2017): Methionine adenosyltransferases in liver health and diseases. Liver Res. **1,** 103-107
https://doi.org/10.1016/j.livres.2017.07.002

Reznick AZ, Packer L (1994): Oxidative damage to proteins: spectrophotometric method for carbonyl assay. Methods Enzymol. **233,** 357-363
https://doi.org/10.1016/S0076-6879(94)33041-7

Savard C, Tartaglione EV, Kuver R, Haigh WG, Farrell GC, Subramanian S, Chait A, Yeh MM, Quinn LS, Ioannou GN (2013): Syneristic interaction of dietary cholesterol and dietary fat in inducing experimental steatohepatitis. Hepatology **57,** 81-92
https://doi.org/10.1002/hep.25789

Smith PK, Krohn RI, Hermanson GT, Mallia AK, Gartner FH, Provenzano MD, Fujimoto EK, Goeke NM, Olson BJ, Klenk DC (1985): Measurement of protein using bicinchoninic acid. Anal. Biochem. **150,** 76-85
https://doi.org/10.1016/0003-2697(85)90442-7

Takahashi Y, Soejima Y, Fukusato T (2012): Animal models of nonalcoholic fatty liver disease/nonalcoholic steatohepatitis. World J. Gastroenterol. **18,** 2300-2308

https://doi.org/10.3748/wjg.v18.i19.2300

Valdés S, Paredes SD, García Carreras C, Zuluaga P, Rancan L, Linillos-Pradillo B, Arias-Díaz J, Vara E (2023): S-adenosylmethionine decreases bacterial translocation, proinflammatory cytokines, oxidative stress and apoptosis markers in hepatic ıschemia-reperfusion ınjury in Wistar rats. Antioxidants (Basel) **12,** 1539
https://doi.org/10.3390/antiox12081539

Vergani L, Baldini F, Khalil M, Voci A, Putignano P, Miraglia N (2020): New perspectives of S-adenosylmethionine (SAMe) applications to attenuate fatty acid-induced steatosis and oxidative stress in hepatic and endothelial cells. Molecules **25,** 4237
https://doi.org/10.3390/molecules25184237

Vincenzi B, Russo A, Terenzio A, Galvano A, Santini D, Vorini F, Antonelli-Incalzi R, Vespasiani-Gentilucci U, Tonini G (2018): The use of SAMe in chemotherapy-induced liver injury. Crit. Rev. Oncol. Hematol. **130,** 70-77
https://doi.org/10.1016/j.critrevonc.2018.06.019

Wang H, Joseph JA (1999): Quantifying cellular oxidative stress by dichlorofluorescein assay using microplate reader. Free Radic. Biol. Med. **27,** 612-616
https://doi.org/10.1016/S0891-5849(99)00107-0

Wortham M, He L, Gyamfi M, Copple BL, Wan YJY (2008): The transition from fatty liver to NASH associates with SAMe depletion in db/db mice fed a methionine choline-deficient diet. Dig. Dis. Sci. **53,** 2761-2774
https://doi.org/10.1007/s10620-007-0193-7

Wu Y, Ma KL, Zhang Y, Wen Y, Wang GH, Hu ZB, Liu L, Lu J, Chen PP, Ruan XC, Liu BC (2016): Lipid disorder and intrahepatic-renin-angiotensin system activation synergically contribute to non-alcoholic fatty liver disease. Liver Int. **36,** 1525-1534
https://doi.org/10.1111/liv.13131

Ye P, Cheah IK, Halliwell B (2013): High fat diets and pathology in guinea pigs. Atherosclerosis or liver damage. Biochim. Biophys. Acta **1832,** 355-364
https://doi.org/10.1016/j.bbadis.2012.11.008

Zhang Y, Si Y, Zhai L, Yang N, Yao S, Sang H, Zu D, Xu X, Qin S, Wang J (2013): Celastrus Orbiculatus Thunb. ameliorates high-fat diet-induced non-alcoholic fatty liver disease in guinea pigs. Pharmazie **68,** 850-854

Received: February 26, 2024
Final version accepted: April 24, 2024